

# Tissue-selective hydrodissection

Multiple options for parenchymal dissection in liver surgery

## Selectivity protects tissue

ERBEJET® 2 with its corresponding applicators enables athermal tissue-selective hydrodissection of the liver<sup>2,8,13,17</sup>. In this process, vascular structures and bile ducts are treated gently in both open surgical and laparoscopic interventions<sup>8,10,14</sup>. Blood vessels and bile ducts can be exposed selectively from the parenchyma and treated in a targeted manner<sup>11,13</sup>.

## Multiple options for parenchymal dissection

ERBEJET® 2 applicators with integrated suction provide a good view of the procedural field and contribute to short surgery times through irrigation and suction<sup>8,10,18,19</sup>. Athermic hydrodissection achieves intact resection margins<sup>2,13,18</sup>. Tumors on the hepatic veins and vena cava can be resected along these structures<sup>11,12,13</sup>. Bile ducts and vessels can, among others, be visualized on the hepatic hilum in various hepatic conditions: healthy liver tissue, cirrhotic liver tissue, or fatty liver<sup>13</sup>.

A clinically significant spread of cancer cells could not be demonstrated<sup>13,14,16</sup>.

### BENEFITS AT A GLANCE

- ☑ Hydrodissection reduces blood loss when compared to other selective dissection techniques<sup>2,13,17</sup>.
- ☑ A low rate of bile leakage is observed during hydrodissection with ERBEJET® 2<sup>1,2</sup>.
- ☑ The need for blood transfusions is reduced<sup>2,13,17</sup>.
- ☑ According to experienced users, hydrodissection with ERBEJET® 2, ESM 2 and applicators is easy and quick to learn<sup>13</sup>.
- ☑ Tissue-selective hydrodissection can reduce the Pringle time or avoid Pringle maneuvers<sup>11,17</sup>.

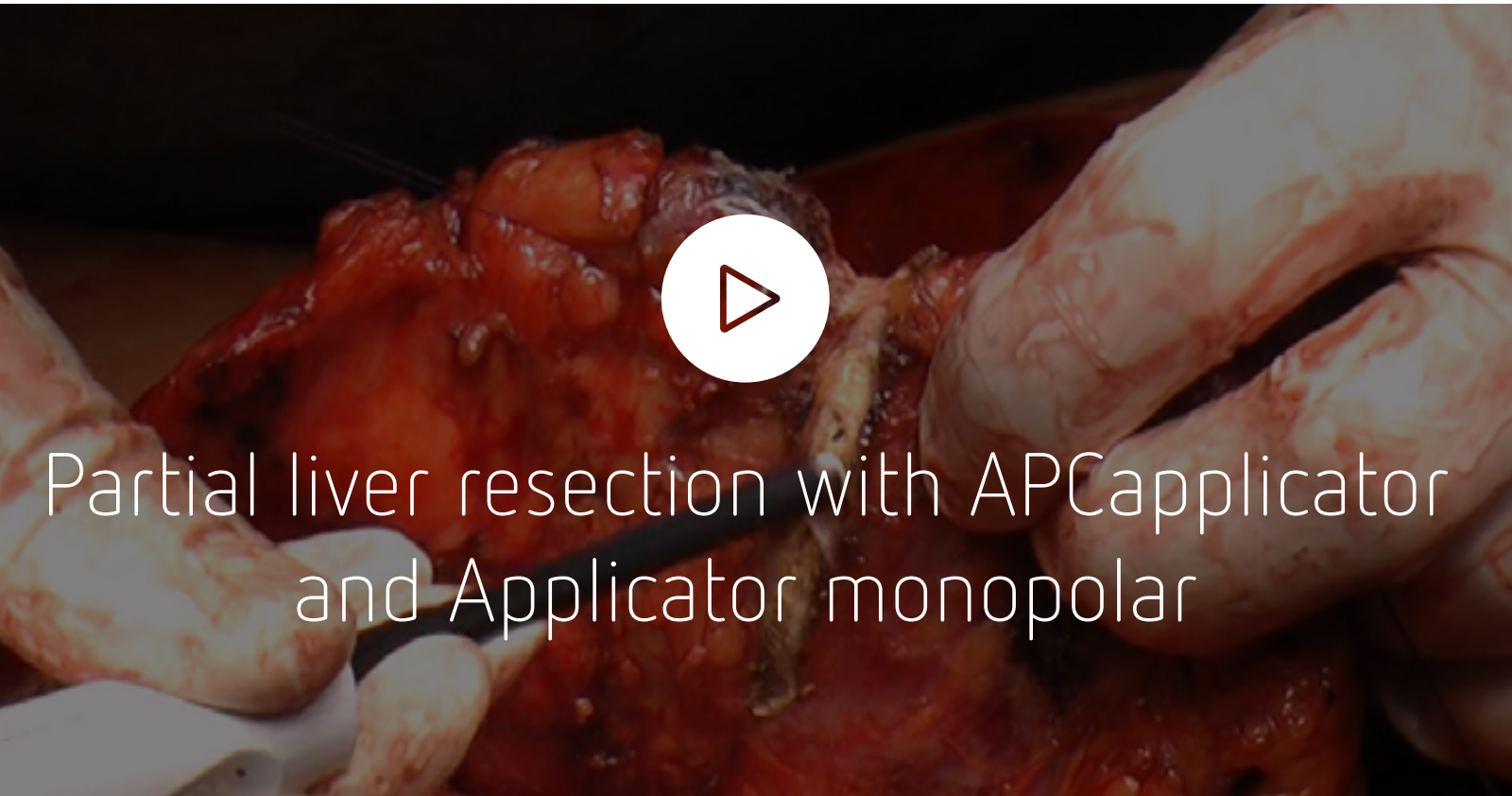
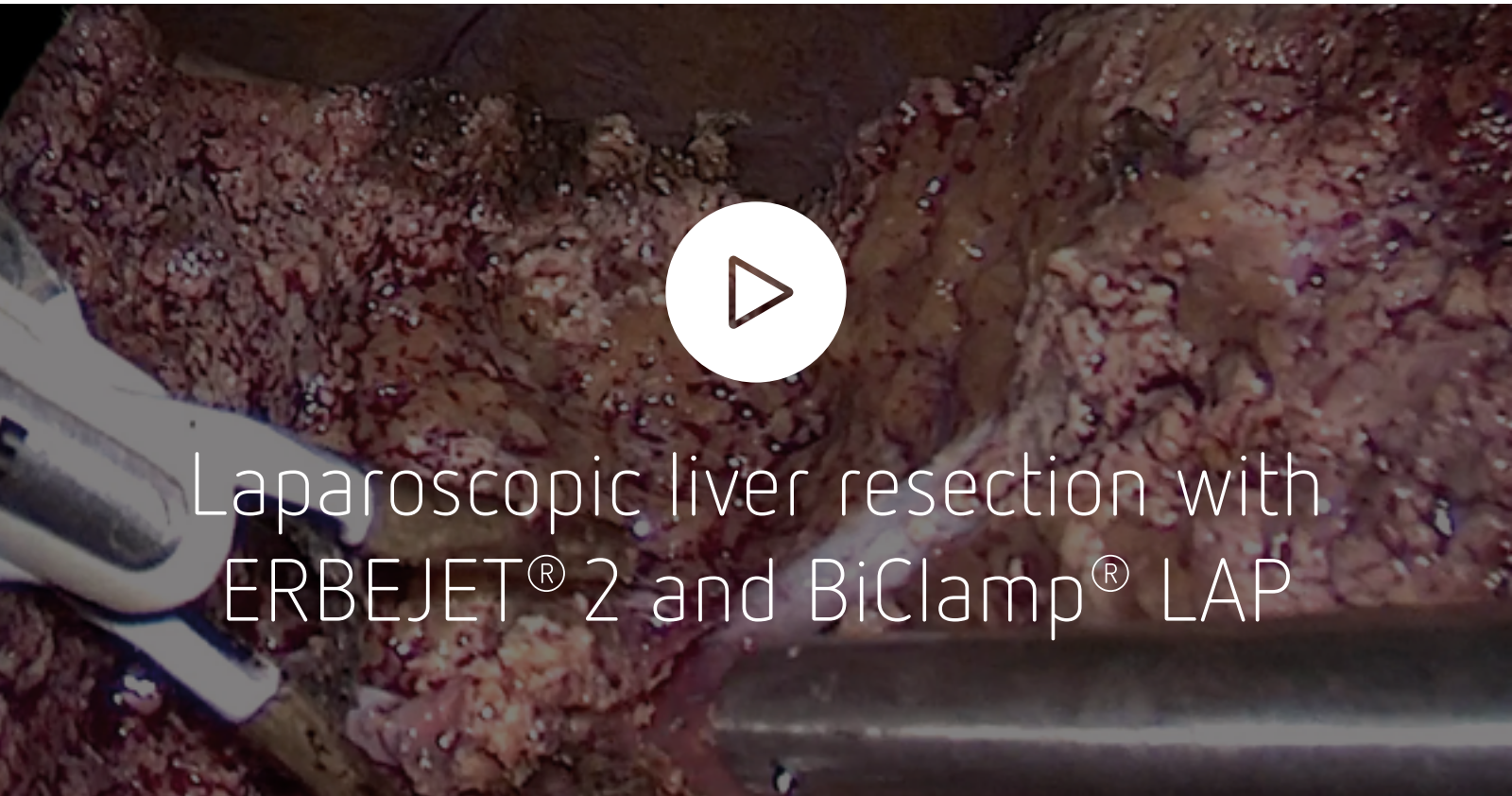*With a higher effect setting, the dissection speed is increased with decreasing selectivity.*

*A low effect setting leads to high selectivity, e.g. in the liver hilum.*

*The monopolar applicator can further increase the dissection speed by simultaneously activated monopolar coagulation and hydrodissection.*







Laparoscopic liver resection with ERBEJET® 2 and BiClamp® LAP

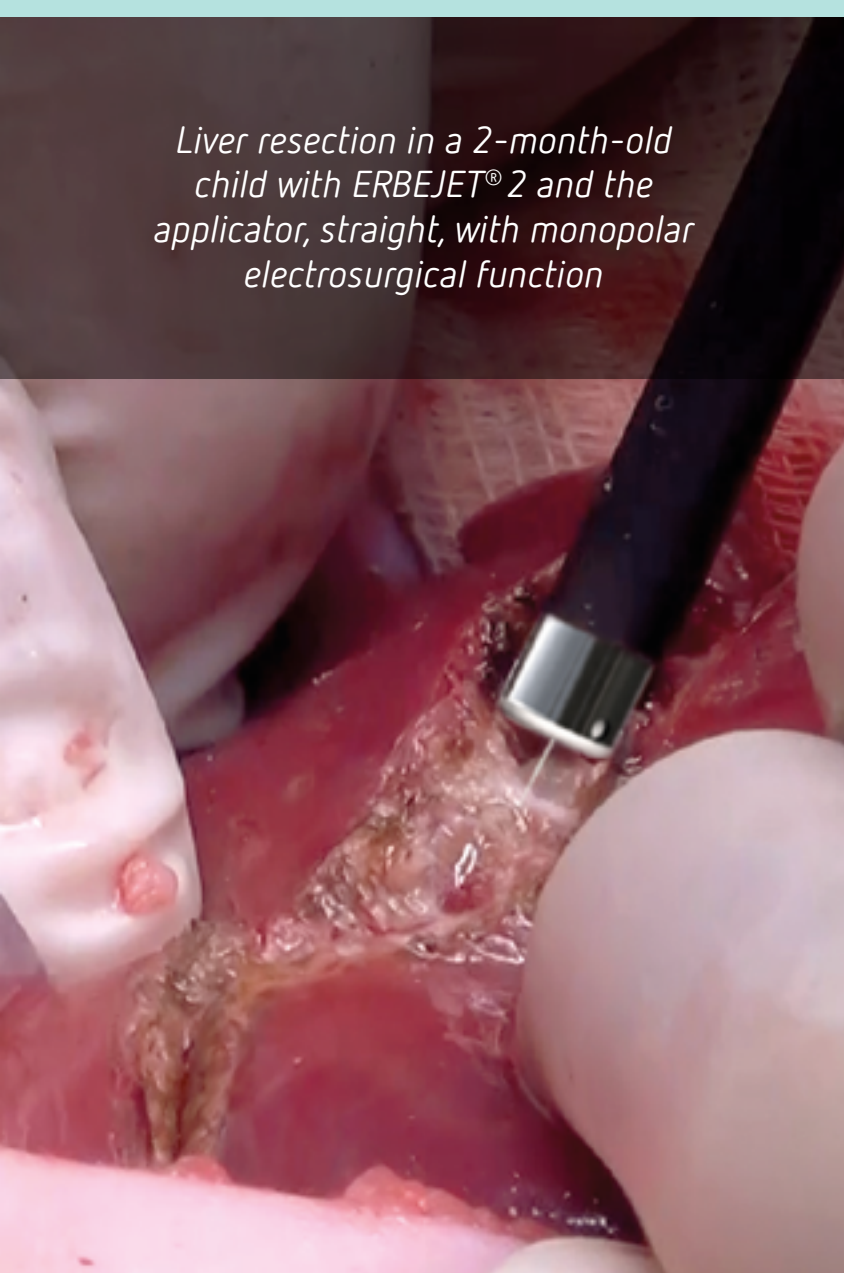Partial liver resection with APCapplicator and Applicator monopolar

**PROF. DR. MIKHAIL EFANOV**

“In laparoscopic liver surgery, ERBEJET® 2 technology ensures a delicate separation of liver tissue, with minimal risk of damage to tubular structures. The minimal damaging effect of the water jet provides the possibility of safe circular exposure of tubular structures, including their separation from the altered surrounding tissues. The combination of irrigation and aspiration in one instrument can accelerate the process of liver parenchyma dissection and provide a stable good visualization of the surgical field.”



*Prof. Dr. Mikhail Efanov*  
MD, PhD, Head of HBP surgery Department of Moscow Clinical Scientific Center, Russian Federation



Liver resection in a 2-month-old child with ERBEJET® 2 and the applicator, straight, with monopolar electro-surgical function

## Applicator with monopolar electro-surgical function

Dissection, coagulation and suction combined in a single instrument

Hydrodissection with this applicator exposes vessels that can be electro-surgically coagulated or dissected depending on the VIO® mode<sup>8,14</sup>. The combination of dissection, coagulation and suction in a single instrument shortens operating time as fewer instrument changes are required<sup>8,9</sup>.

The monopolar applicator can further increase the dissection speed by simultaneously activated monopolar electro-surgical function and hydrodissection<sup>19</sup>. Bleeding, which is already at a low level due to the technique, is further reduced, making coagulation more homogeneous and less necrotic<sup>7</sup>. Diffuse parenchymal hemorrhage is also easy to coagulate with the monopolar applicator<sup>3,4,5</sup>.

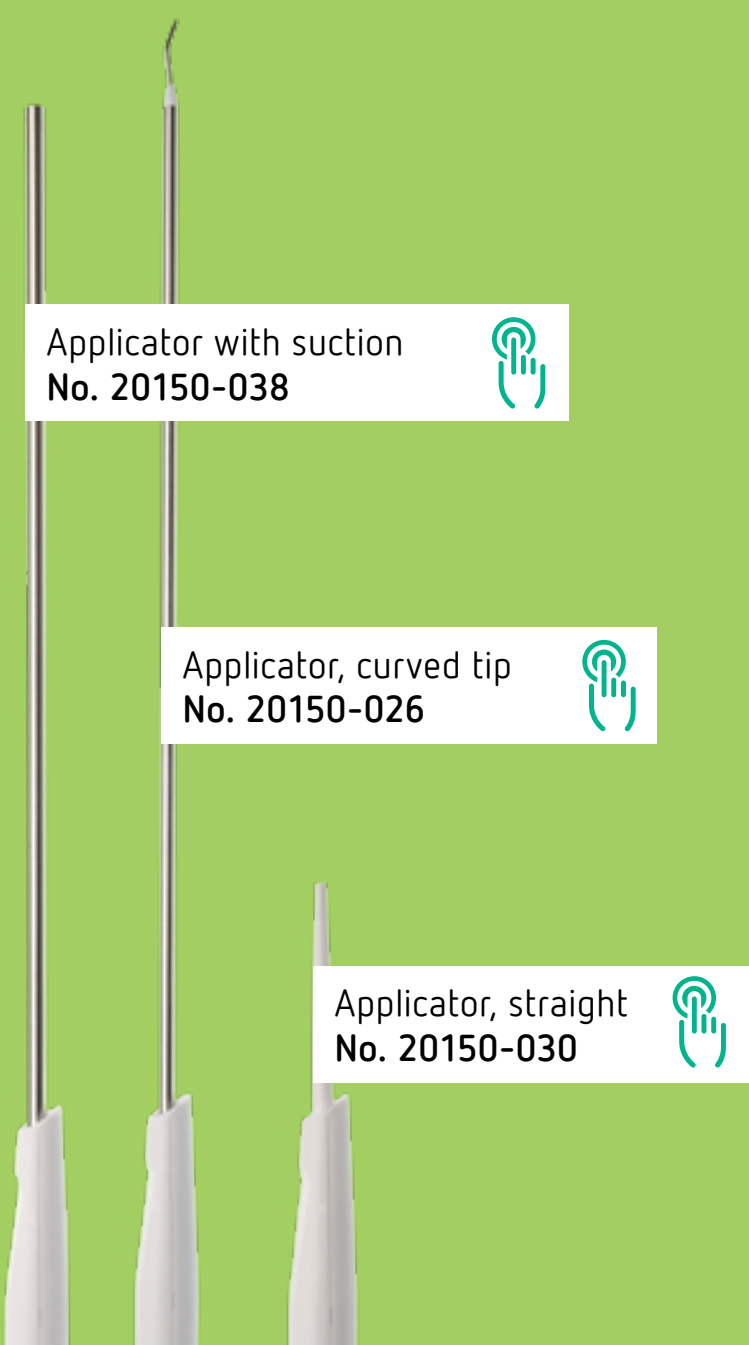


## The system

ERBEJET® 2 is compatible with the VIO® 3 Workstation and can be used as a module or as an individual unit in the OR. The combination of the two technologies – electro-surgery and hydrosurgery – is unique. The applicators are supplied as sterile, disposable products which can be used immediately and offer consistent quality and safety.



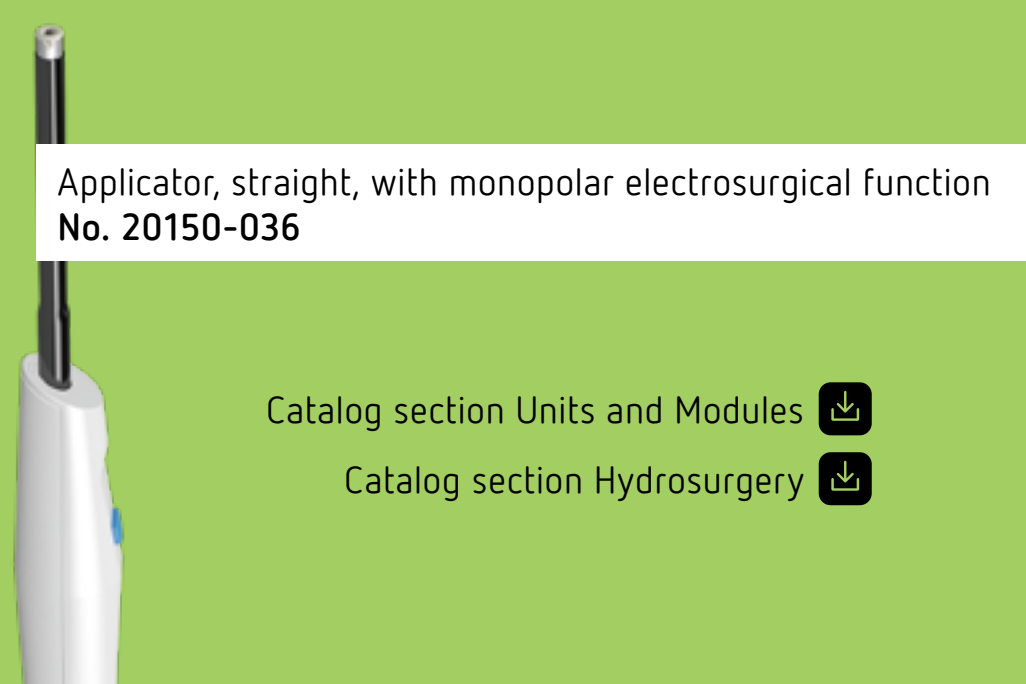
**Surgery workstation:**  
VIO® 3 Electro-surgery  
APC 3 Plasmasurgery  
ERBEJET® 2 Hydrosurgery  
ESM 2 suction module



Applicator with suction  
No. 20150-038


Applicator, curved tip  
No. 20150-026

Applicator, straight  
No. 20150-030



Applicator, straight, with monopolar electro-surgical function  
No. 20150-036

Catalog section Units and Modules  
Catalog section Hydrosurgery





## References

- 1 Kamarajah SK, Wilson CH, Bundred JR et al. A systematic review and network meta-analysis of parenchymal transection techniques during hepatectomy: an appraisal of current randomised controlled trials. *HPB (Oxford)* 2019
- 2 Hamaoka M, Kobayashi T, Kuroda S et al. Experience and outcomes in living donor liver procurement using the water jet scalpel. *J Hepatobiliary Pancreat Sci* 2019; 26: 370–376
- 3 Hamada T, Nanashima A, Yano K et al. Significance of a soft-coagulation system with monopolar electrode for hepatectomy: A retrospective two-institution study by propensity analysis. *Int J Surg* 2017; 45: 149–155
- 4 Sharoyev T. Liver resection on a newborn child with ERBEJET® 2. [www.medical-videos.com](http://www.medical-videos.com) 2017
- 5 Rau MD. Hepatectomy, left lateral, with the Surgical Workstation: General and visceral surgery. D090060. [www.medical-videos.com](http://www.medical-videos.com) 2017
- 6 Maurer CA, Walensi M, Käser SA et al. Liver resections can be performed safely without Pringle maneuver: A prospective study. *World J Hepatol* 2016; 8: 1038–1046
- 7 Kennedy-Smith et al. V5-08 zero Ischemia laparoscopic partial nephrectomy for T2 kidney cancer using a saline-jet dissector, [j.juro.2015.02.1476](http://j.juro.2015.02.1476)
- 8 Yu S, Gao Z, Lin C et al. Waterjet dissection for partial nephrectomy without hilar clamping in a porcine model. *Int Surg* 2014; 99: 677–680
- 9 Zambon V, Bruin M de, Delaere F et al. P143 Non-clamping partial nephrectomy by hydrodissection. *European Urology Supplements* 2014; 13: 163
- 10 Gao Y, Chen L, Ning Y et al. Hydro-Jet-assisted laparoscopic partial nephrectomy with no renal arterial clamping: a preliminary study in a single center. *Int Urol Nephrol* 2014; 46: 1289–1293
- 11 Rau HG, Duessel AP, Wurzbacher S. The use of water-jet dissection in open and laparoscopic liver resection. *HPB (Oxford)* 2008; 10: 275–280
- 12 Poon RTP. Current techniques of liver transection. *HPB (Oxford)* 2007; 9: 166–173
- 13 Vollmer CM, Dixon E, Sahajpal A et al. Water-jet dissection for parenchymal division during hepatectomy. *HPB (Oxford)* 2006; 8: 377–385
- 14 Moinzadeh A, Hasan W, Spaliviero M et al. Water jet assisted laparoscopic partial nephrectomy without hilar clamping in the calf model. *J Urol* 2005; 174: 317–321
- 15 Lesurtel et al. How should transection of the liver be performed?: a prospective randomized study in 100 consecutive patients: comparing four different transection strategies. *Ann Surg.* 2005 Dec;242(6):814-22, discussion 822-3
- 16 Shekarriz B, Upadhyay J, Jewett MAS. Nerve-sparing retroperitoneal lymphadenectomy using hydro-jet dissection: initial experience. *J Endourol* 2004; 18: 273–276
- 17 Rau HG, Wichmann MW, Schinkel S et al. Surgical techniques in hepatic resections: Ultrasonic aspirator versus Jet-Cutter. A prospective randomized clinical trial. *Zentralbl Chir* 2001; 126: 586–590
- 18 Basting RF, Djakovic N, Widmann P. Use of water jet resection in organ-sparing kidney surgery. *J Endourol* 2000; 14: 501–505
- 19 Internal Data on file: D168238